Fibro-osseous Lesions

characterized microscopically by fibrous stroma containing various combinations of bones and/or cementum-like material

Fibrous Dysplasia (FD):

- The condition presents commonly an asymptomatic, slow enlargement of the involved bone.

A

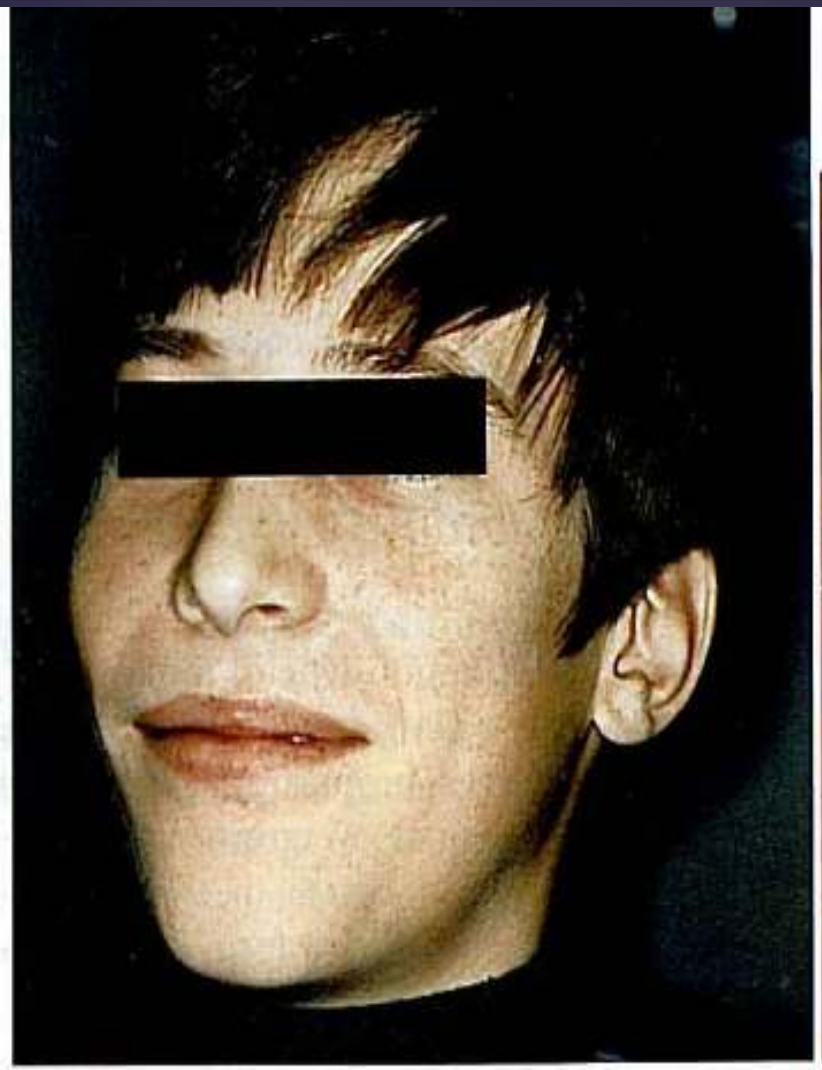

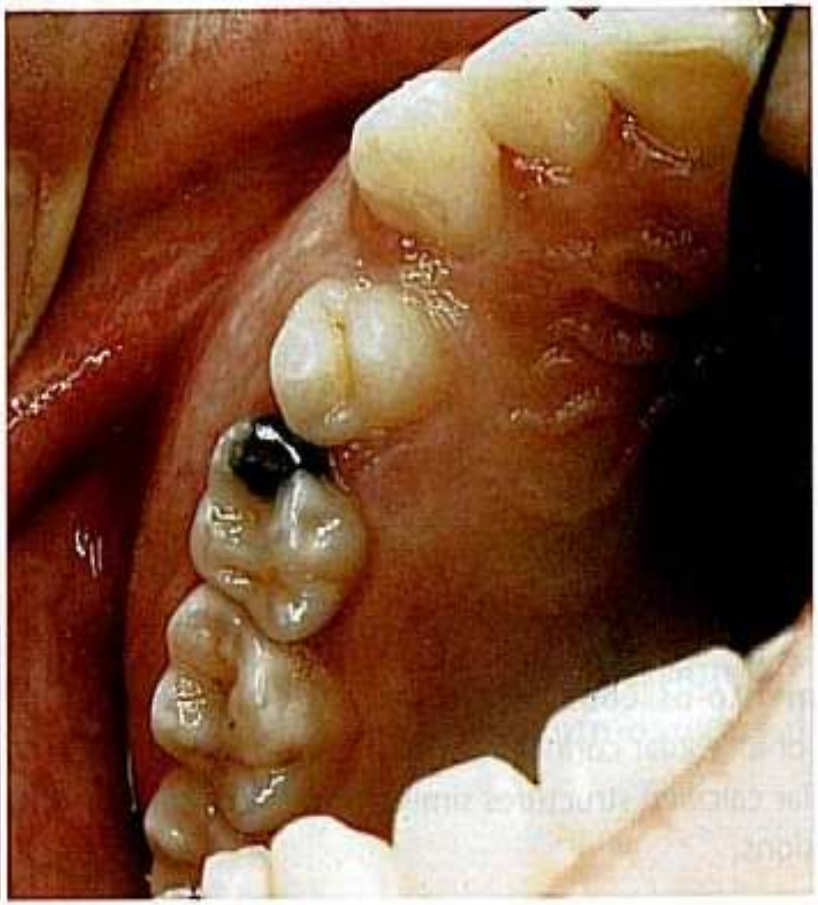

B

Juvenile fibrous dysplasia. A, Facial asymmetry caused by expansile lesion of right maxilla. **B,** Diffuse buccal and lingual expansion of right alveolar process exhibiting displacement of first premolar and retained primary molar. (Courtesy Dr. Alan M. Coote and Dr. Douglas W. Stoneman.)

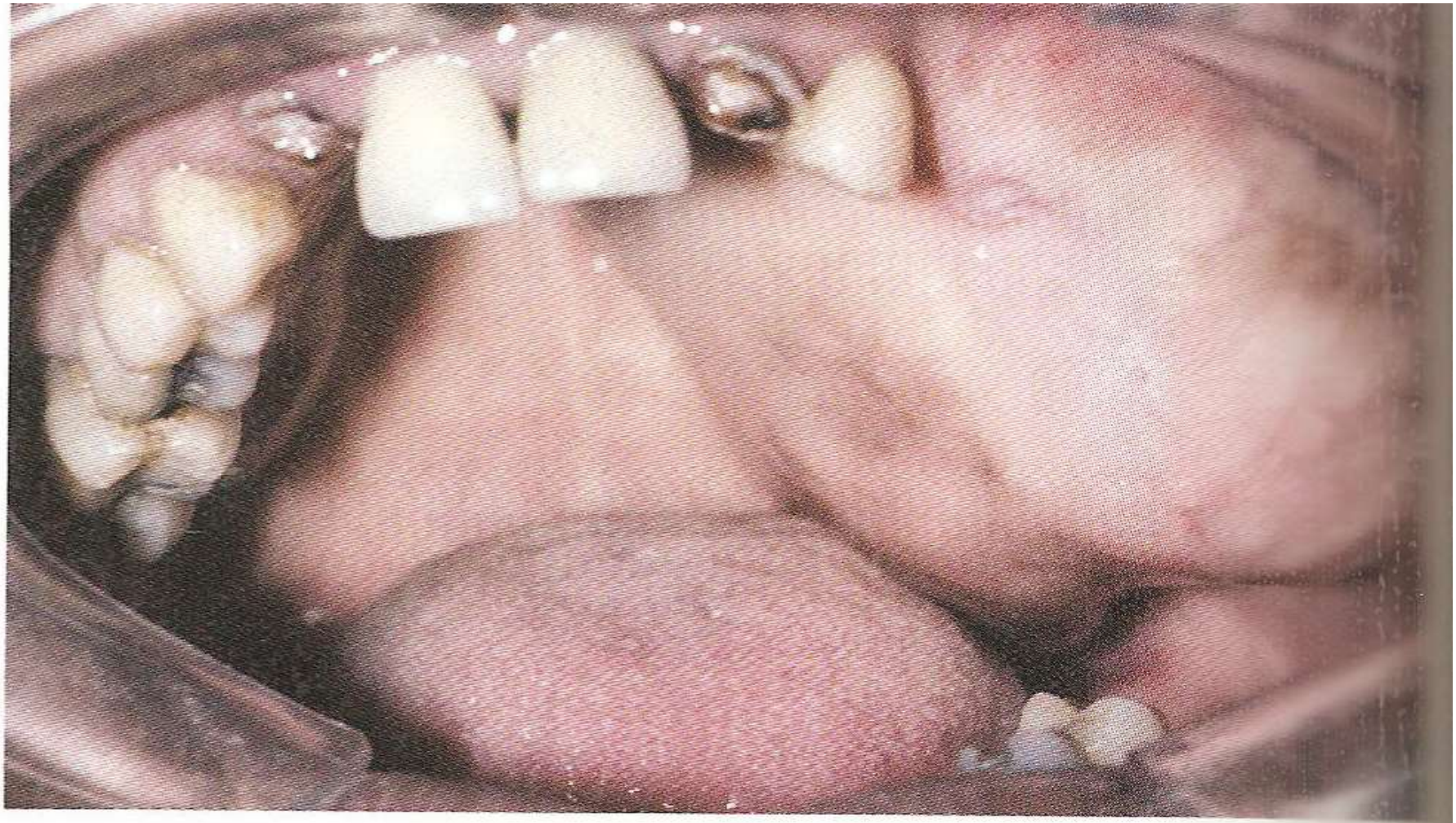

Fibrous dysplasia. Expansile mass of the left maxilla in a 45-year-old woman. This lesion was known to have been present for at least 20 years.

McCune-Albright syndrome consists of polyostotic FD, cutaneous melanotic pigmentations (*café-au-lait macules*) and endocrine abnormalities.

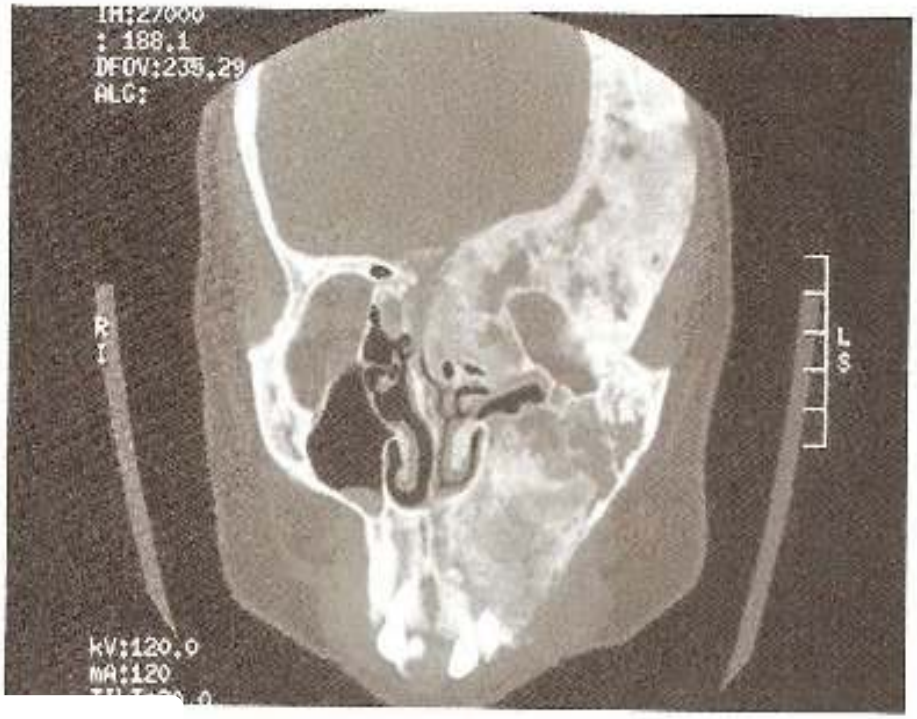

Fig. 14-36 **Fibrous dysplasia.** Computed tomography (CT) image showing extensive involvement of the maxilla and skull.

Polyostotic fibrous dysplasia. Jaffe-Lichtenste syndrome. *Café au lait* pigmentation of the abdomen. This the same patient as shown in Fig. 14-37.

A

C

Polyostotic fibrous dysplasia. Jaffe-Lichtenstein syndrome. **A,** Young man exhibiting enlargement of the right maxilla and mandible. **B,** Intraoral photograph showing unilateral maxillary expansion. **C,** Panoramic radiograph showing ill-defined lesions of the right side of both jaws.

Fibrous dysplasia: Periapical radiograph showing a diffuse "**ground-glass**" appearance, results from the superimposition of poorly calcified bone trabeculae arranged in a disorganized pattern**.**

Fibrous dysplasia

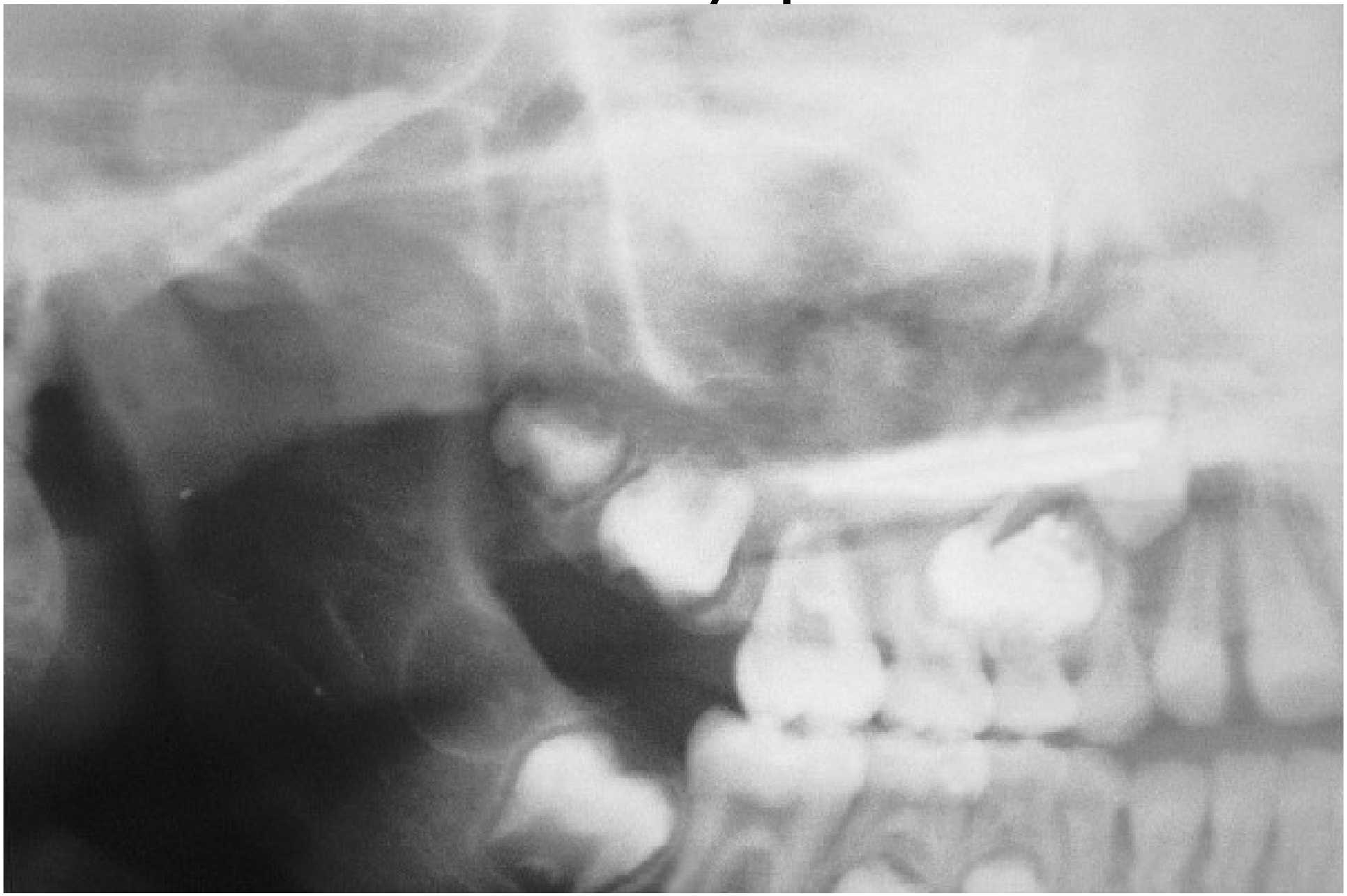

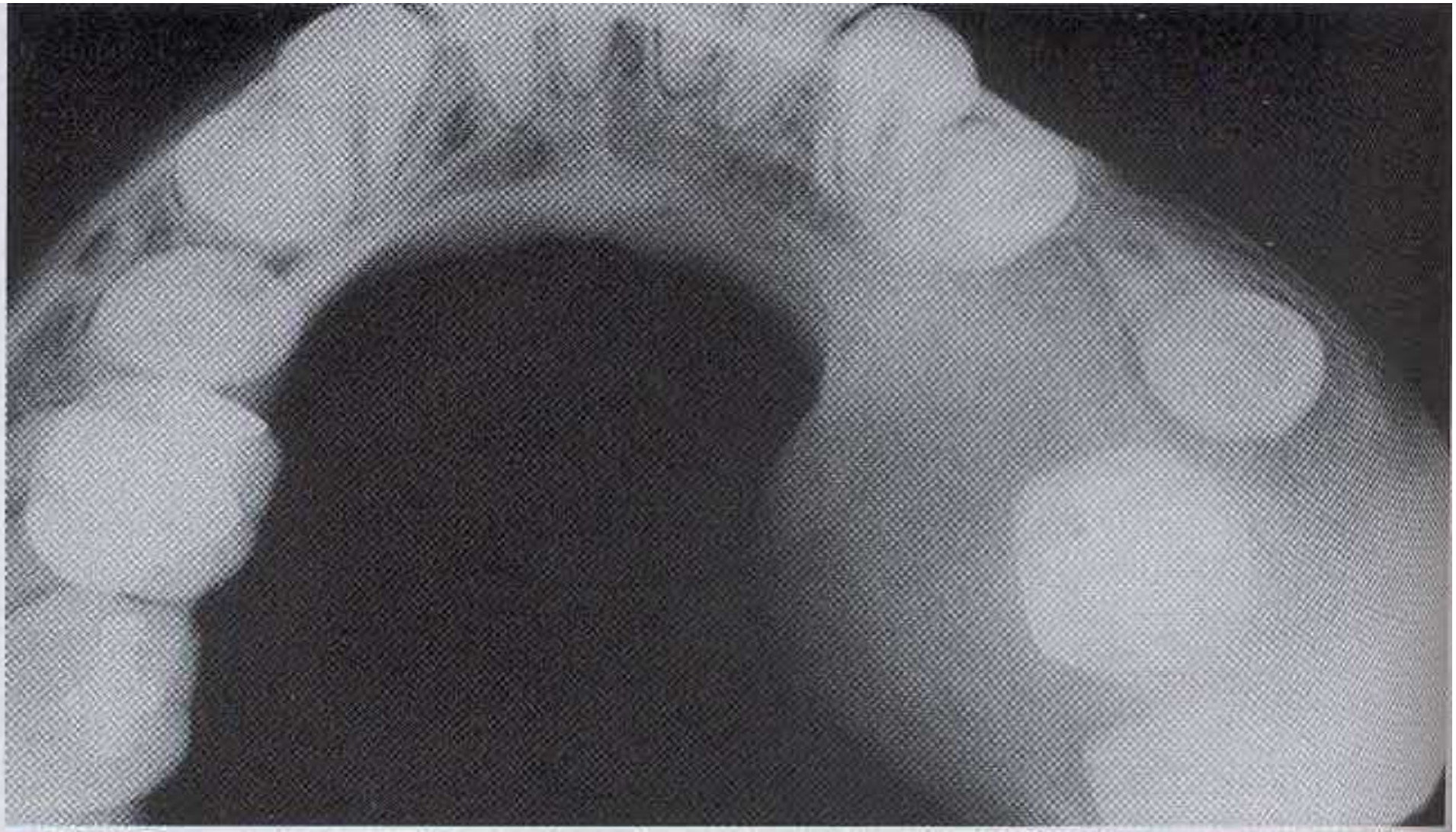

Figure 14-34 • Fibrous dysplasia. Occlusal radiograph showing localized expansion of the mandible and the "ground-glass" radiographic appearance. The margins of the lesion are not well defined and blend into the adjacent bone. (From Waldron CA,

- **Histopathology:**
- FD consists of a slight to moderate cellular fibrous connective tissue stroma that contains foci of irregularly shaped trabeculae of immature bone. The bone trabeculae assume irregular shapes linked to ***Chinese characters***

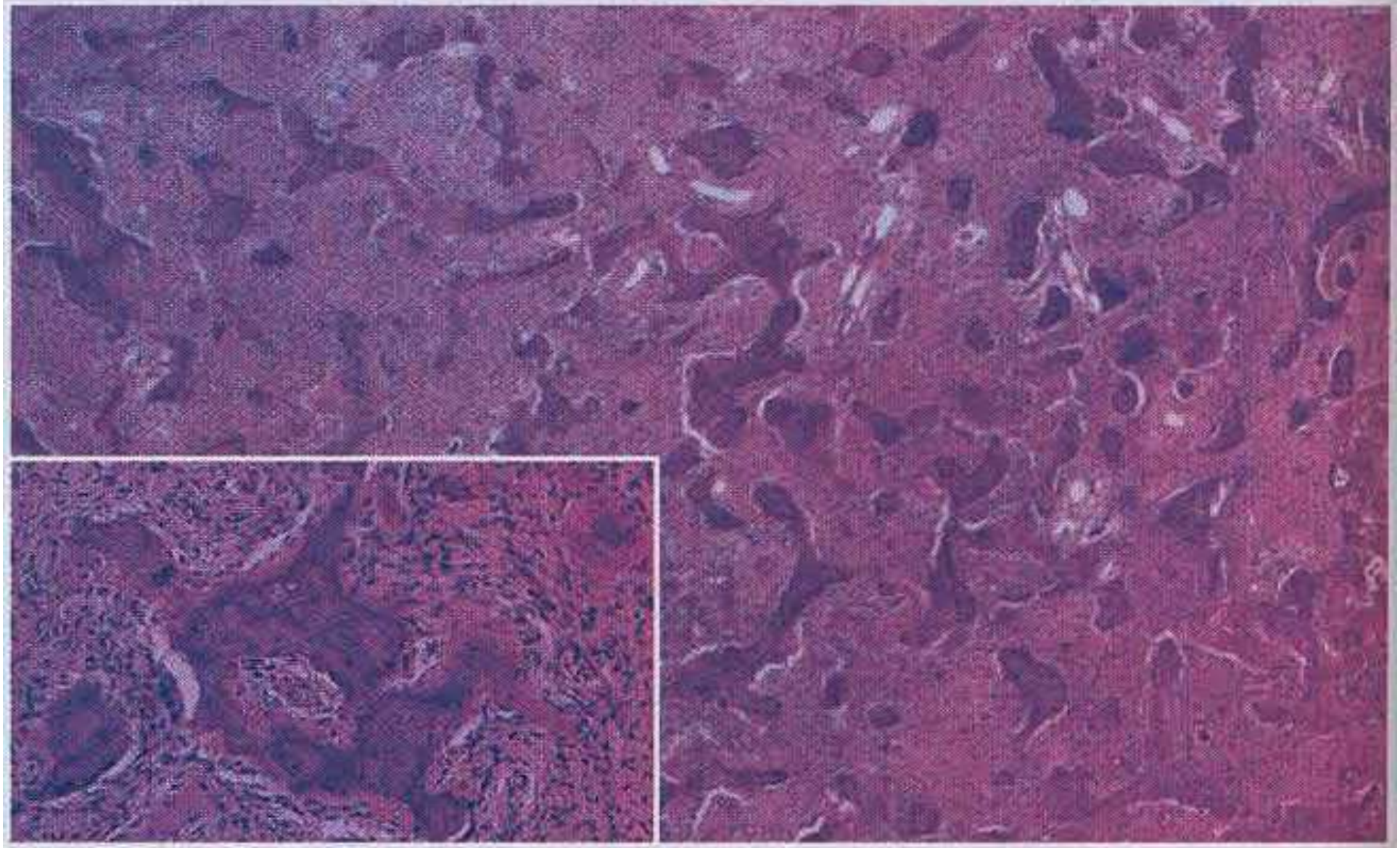

Figure 14-38 • Fibrous dysplasia. Irregularly shaped trabeculae of woven bone in a fibrous stroma.

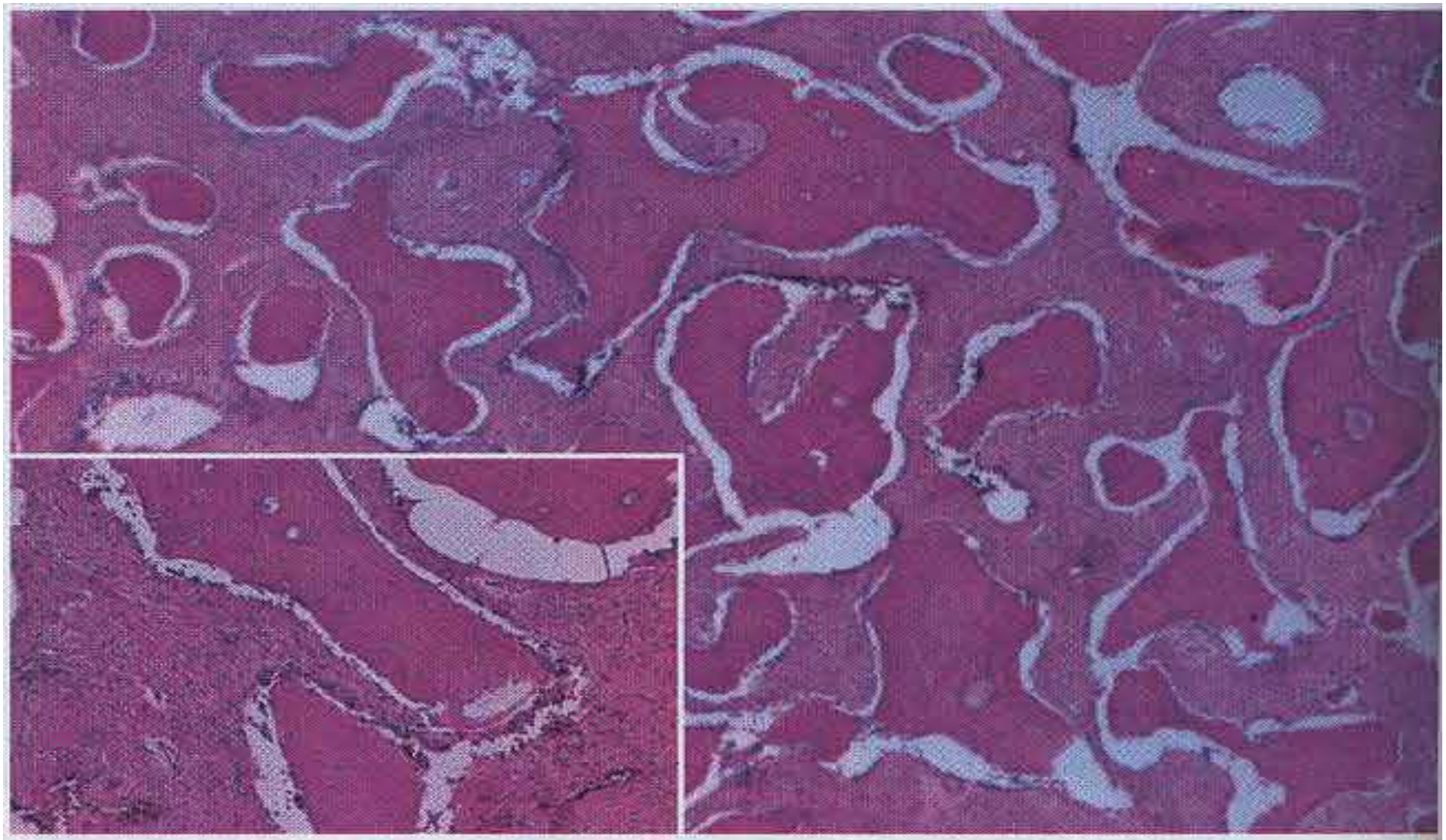

Figure 14-39 • Mature fibrous dysplasia. This long-standing lesion shows scattered trabeculae of bone within fibrous connective tissue. Note the lamellar maturation of the bone.

Fibrous dysplasia exhibiting fibroblastic matrix and uniform distribution of bony trabeculae (purple, not decalcified).

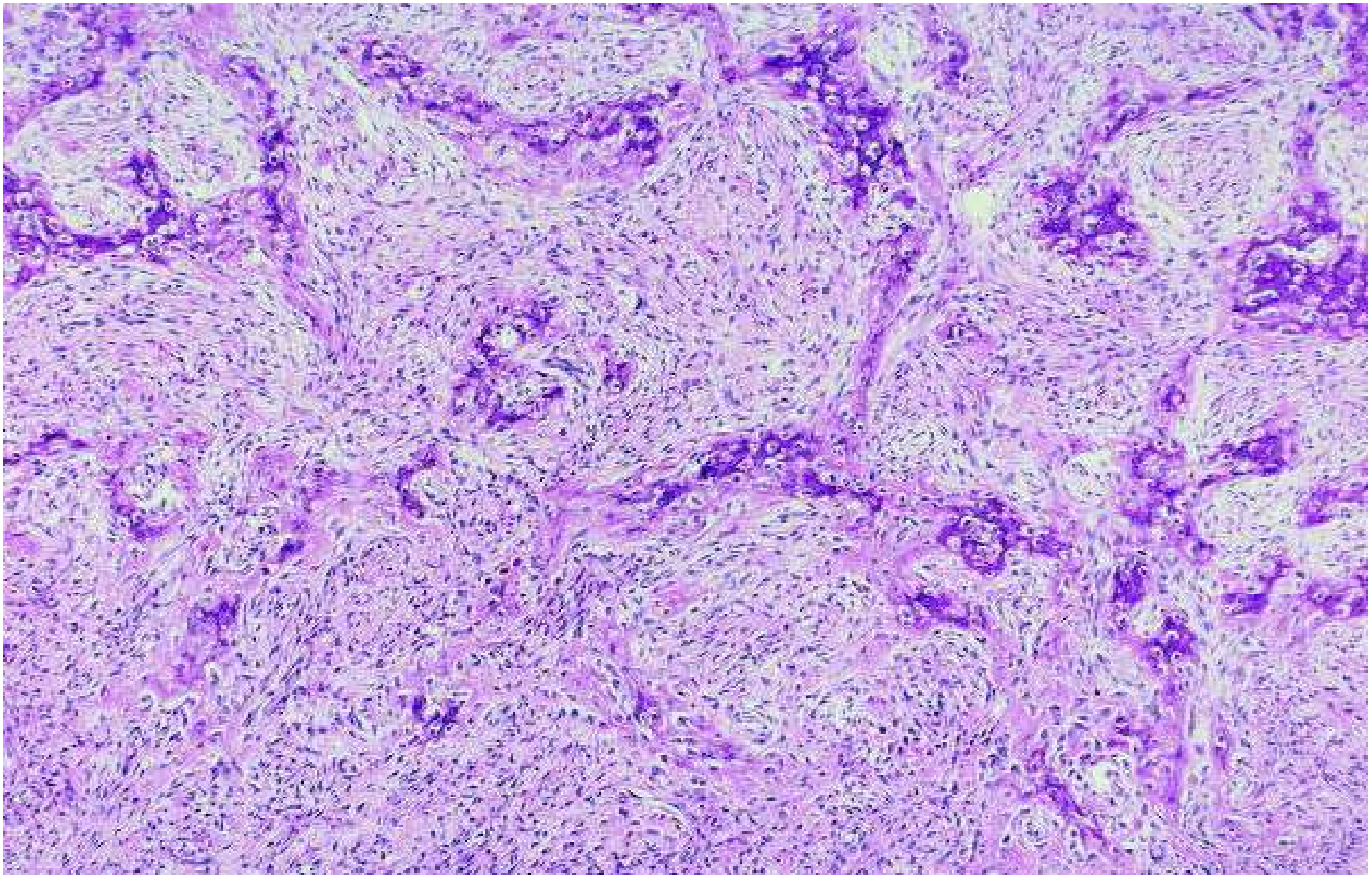

Fibrous dysplasia: showing vascular fibroblastic matrix and irregular trabeculae of new bone.

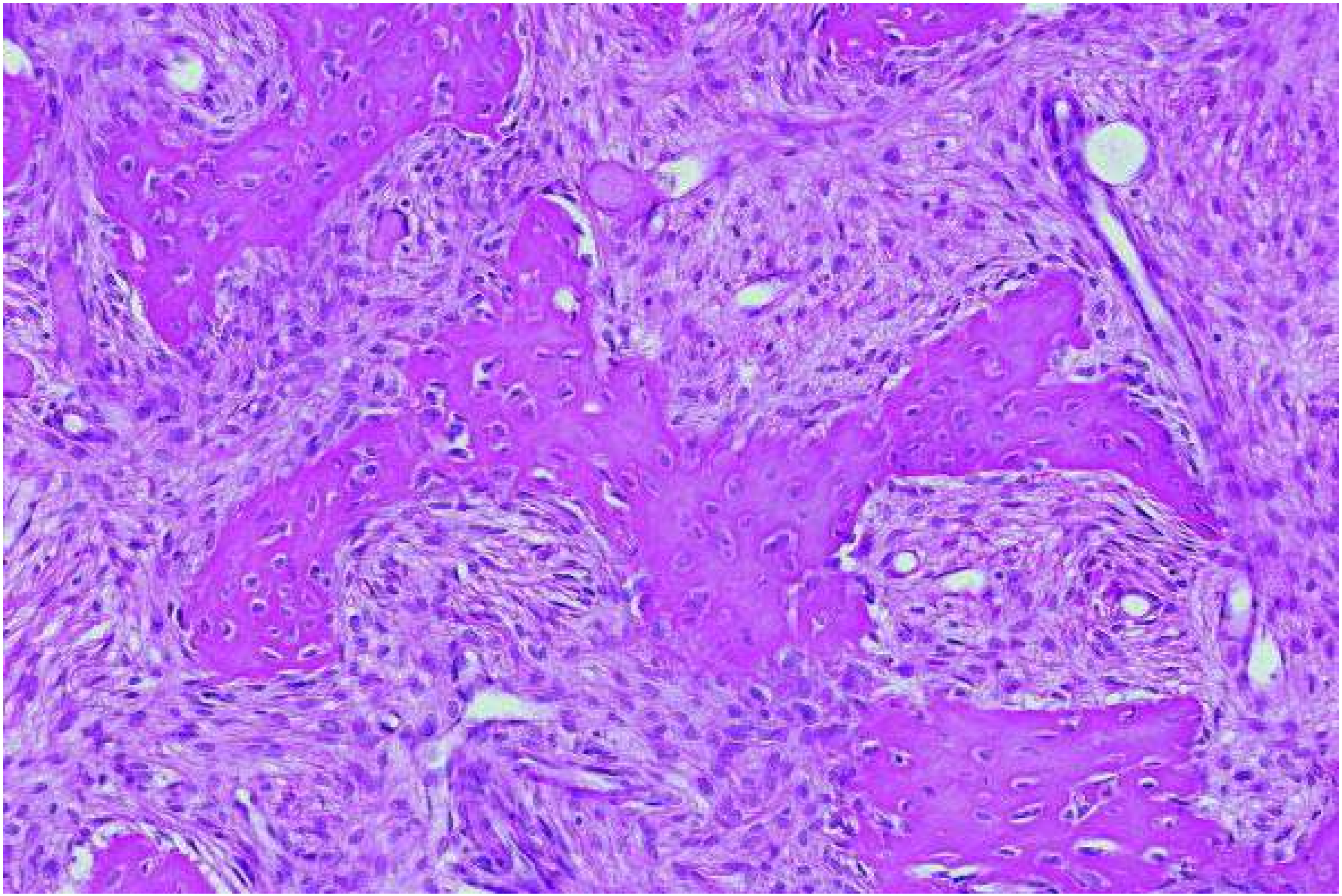

Ossifying fibroma: Gross specimen showing a well-circumscribed tumor that shelled out in one piece.

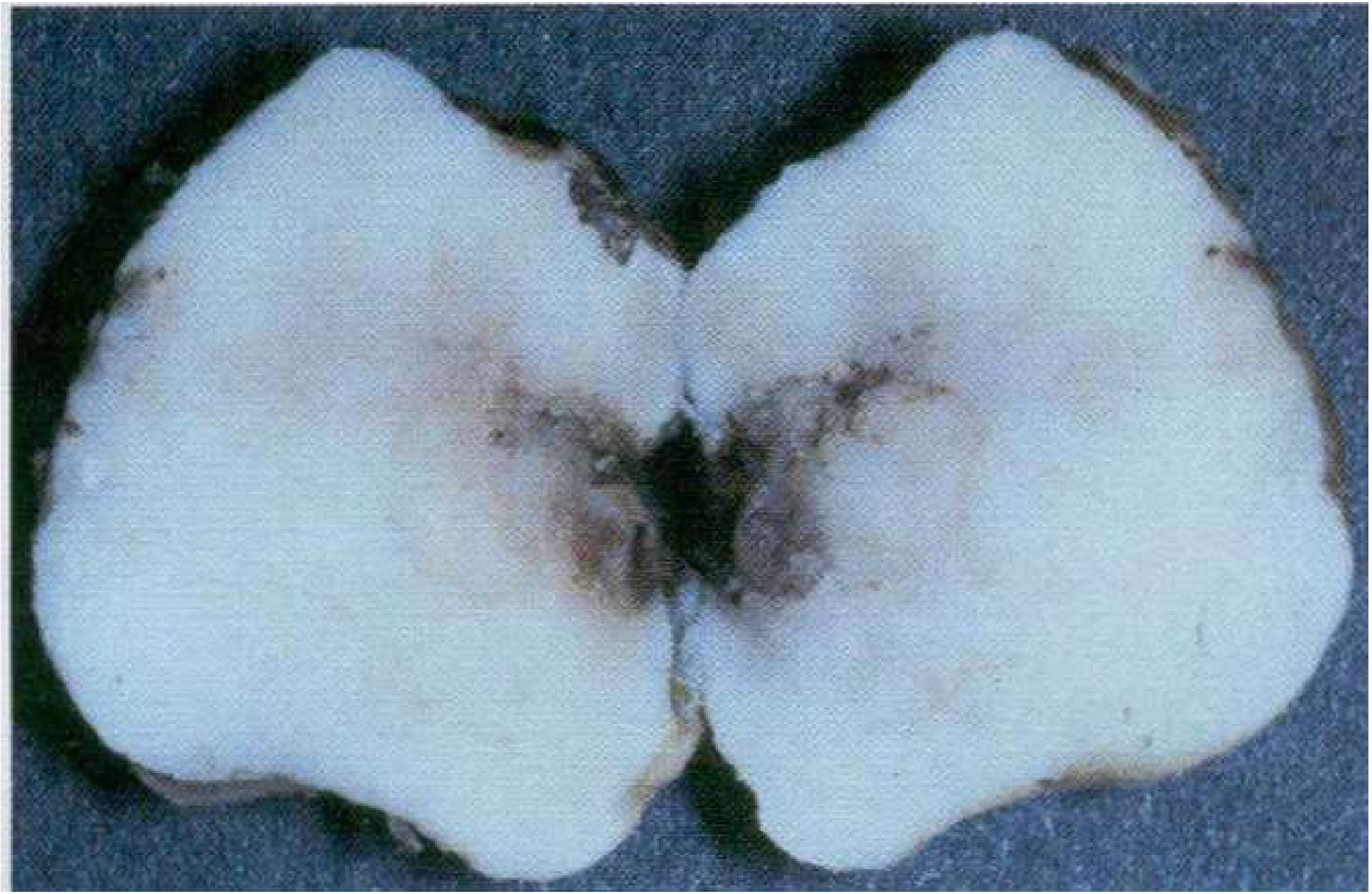

B

Fig. 14-52 Ossifying fibroma. A, Enlargement of the posterior maxilla caused by a large ossifying fibroma. **B,** Note the mixed radiolucent and radiopaque lesion expanding the posterior maxilla.

Radiographic Findings of COF:

- **Well circumscribed**, sharply demarcated border is the most common presenting radiographic feature.
- mixed **radiolucent-radiopaque** image may be seen.
- **The roots** of the teeth present may be displaced & less commonly resorption is seen.

Ossifying fibroma

Ossifying fibroma: This low-magnification photomicrograph shows a well-circumscribed solid tumor mass. Trabeculae of bone and droplets of cement um-like material can be seen forming within a background of cellular fibrous connective tissue.

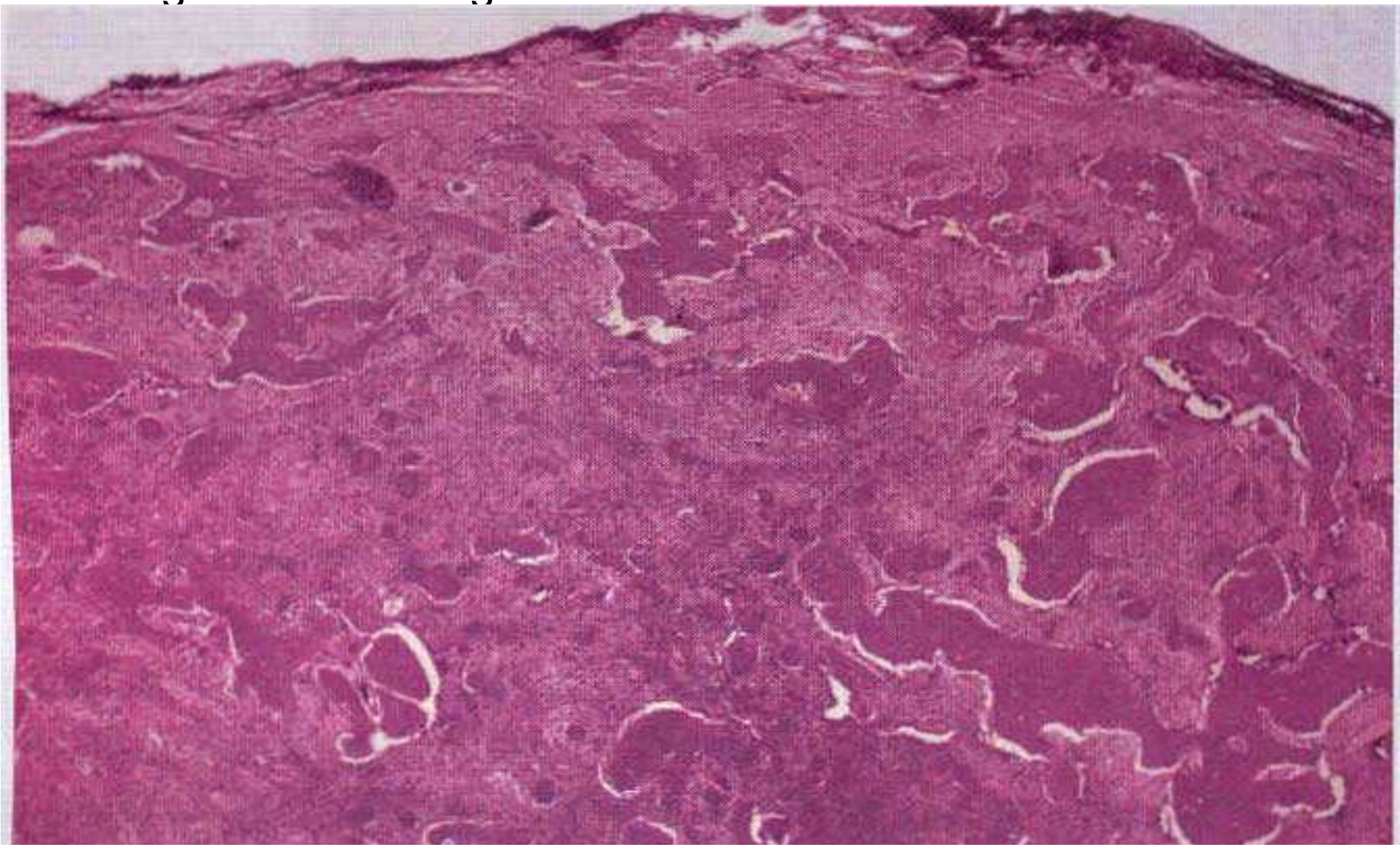

Ossifying fibroma: High-power photomicrograph showing a mixture of woven bone and cementum-like material.Note the spherules demonstrating peripheral brush borders *(arrow).*

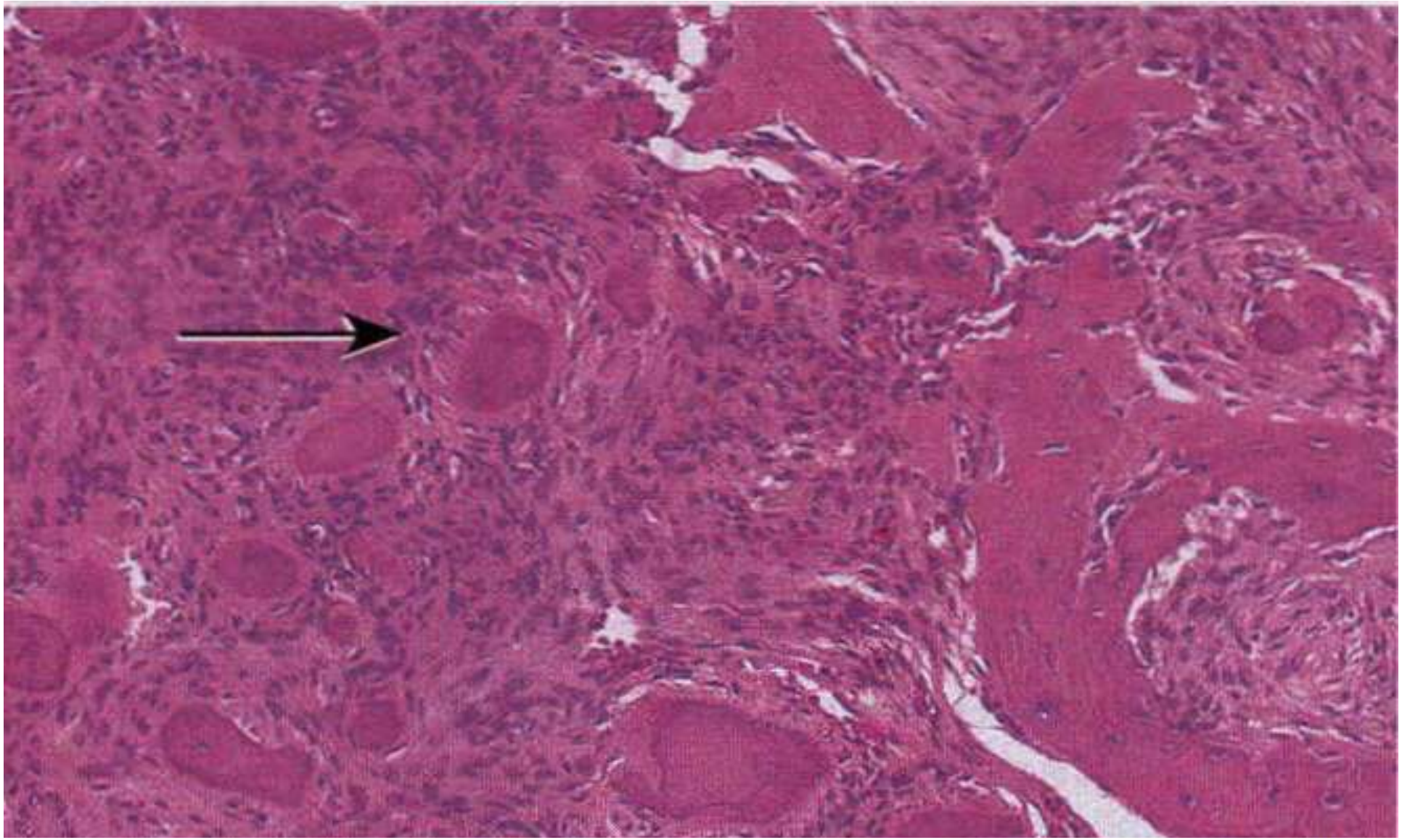

- ***<u>Cemento-osseous Dysplasia (COD):</u>***
  Includes:
- Periapical COD.
- Focal COD.
- Florid COD.
- All the 3 disease processes have the same features, only distinguished on the basis of the extent of involvement of the affected portions of the jaw.

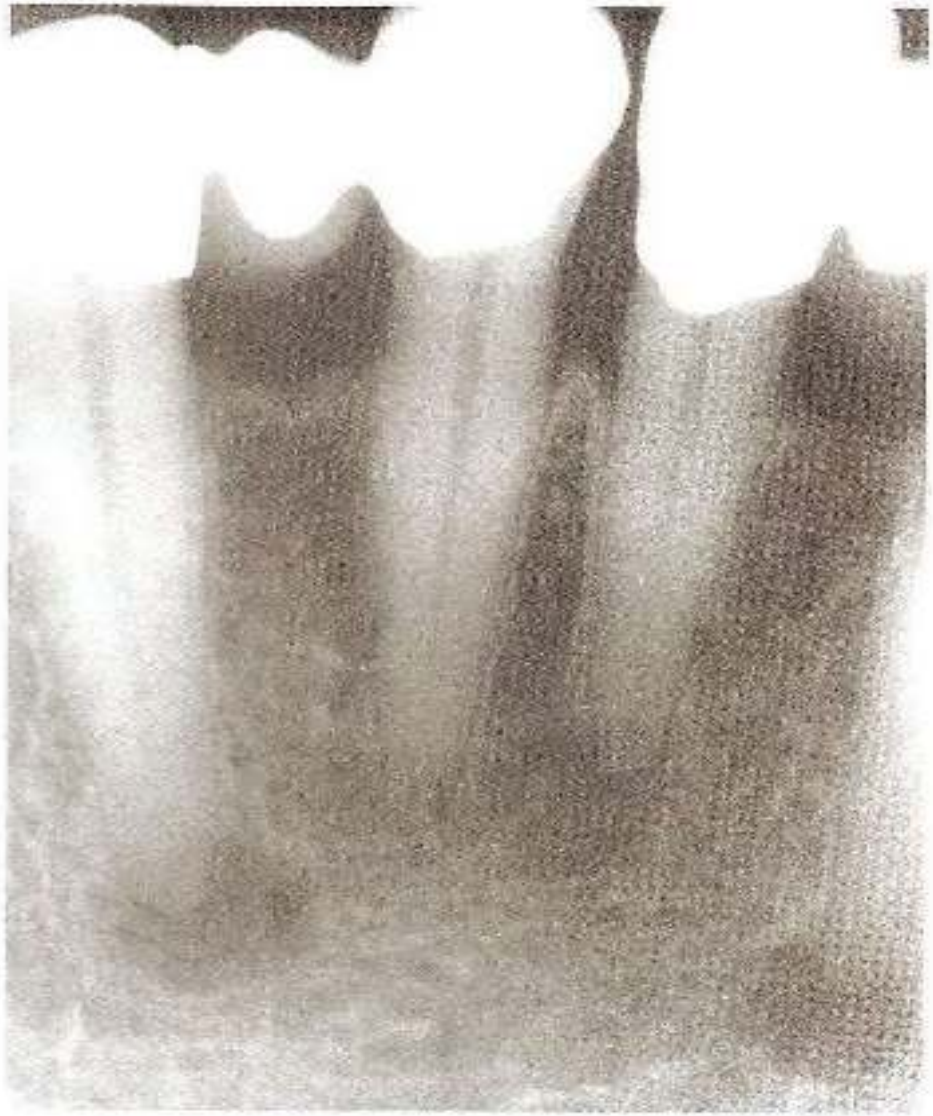

Fig. 14-42 Periapical cemento-osseous dysplasia. Periapical radiograph showing multiple radiolucent lesions at the apices of the anterior mandibular teeth. *(Courtesy of Dr. Aaron Carner.)*

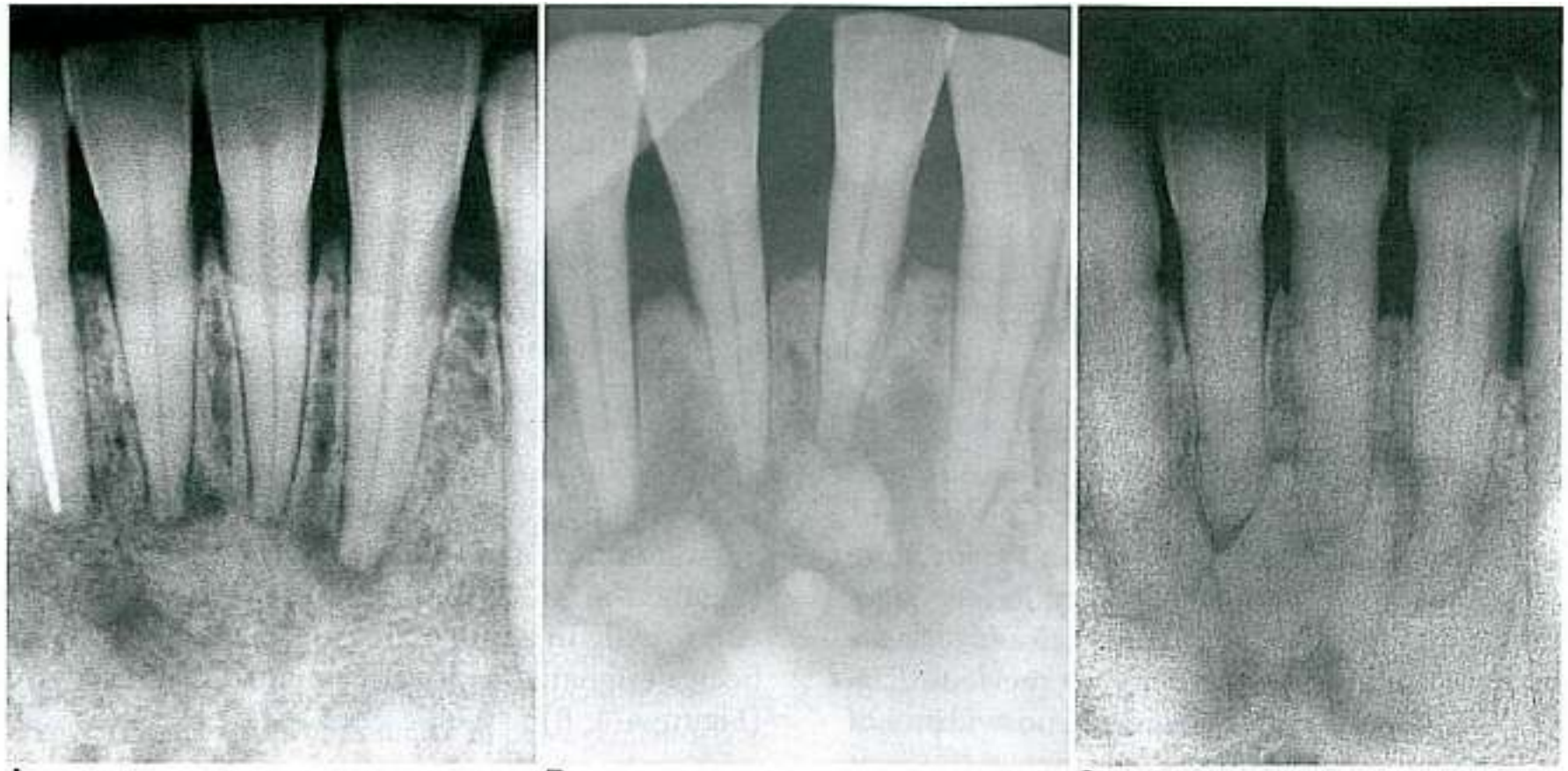

A B C

FIGURE 4-2

Periapical cemental dysplasia. Radiographic features of osteolytic **(A)**, cementoblastic **(B)**, and mature stages **(C)**.

Periapical cemento-osseous dysplasia

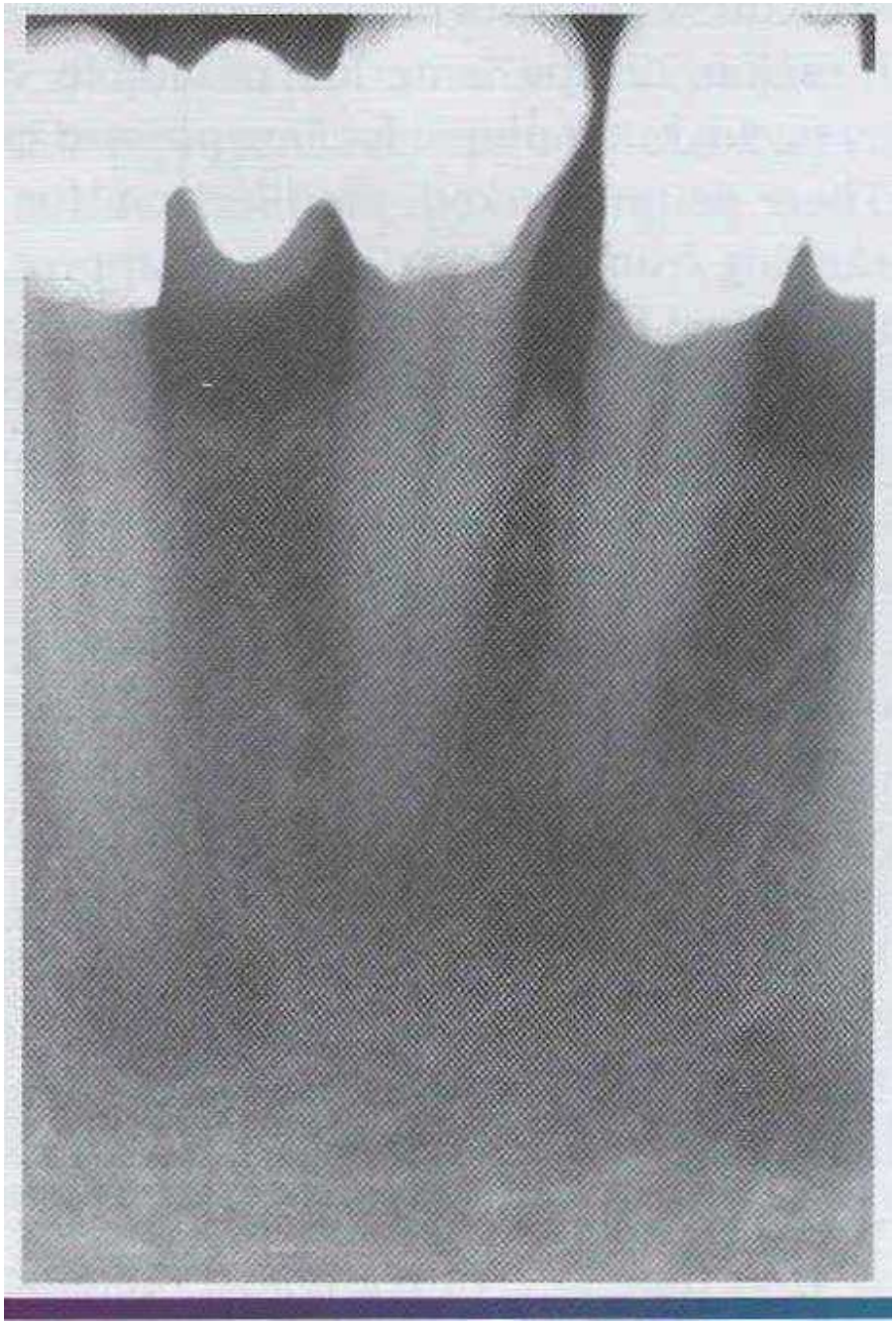

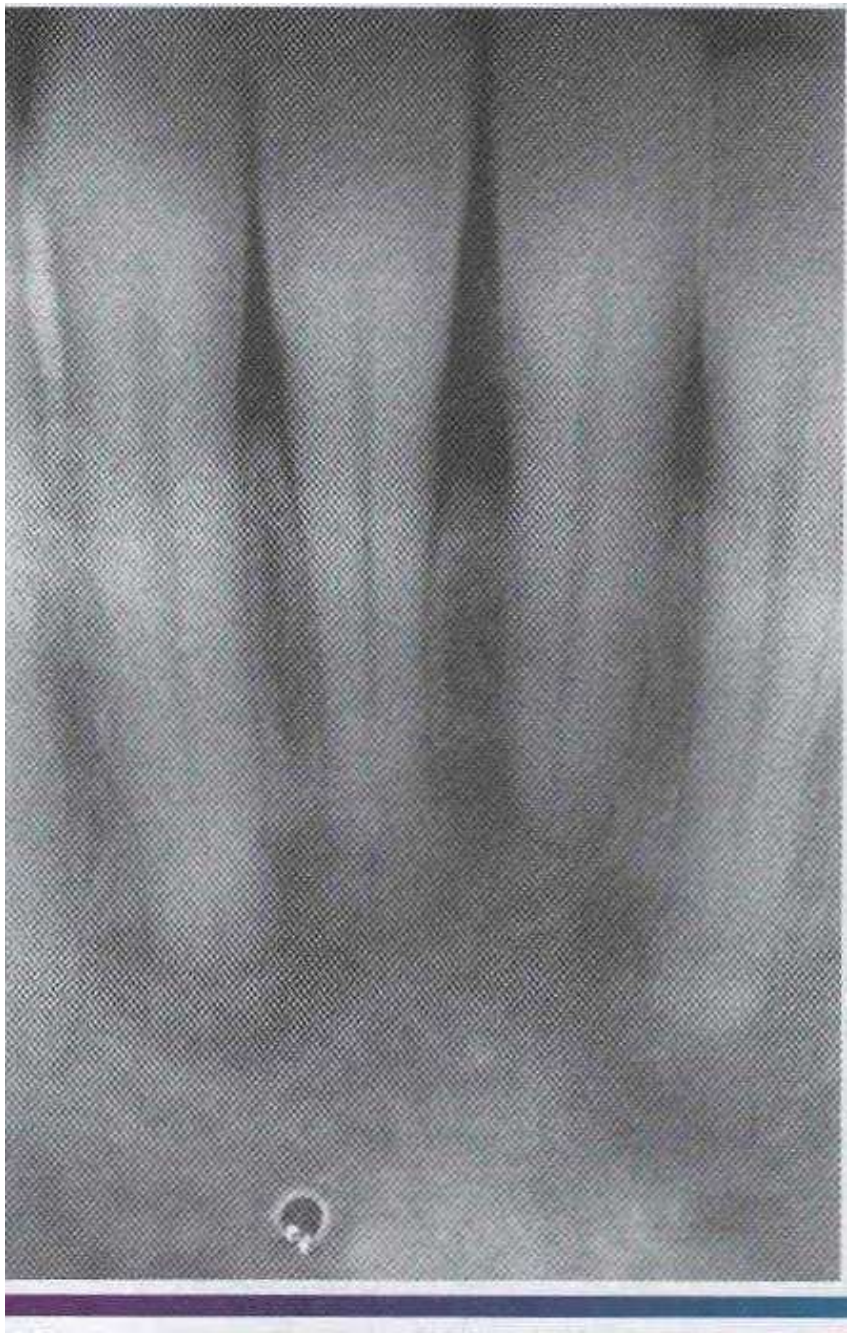

Fig. 14-43 Periapical cemento-osseous dysplasia. Later-stage lesions exhibiting significant mineralization.

Fig. 14-44 Periapical cemento-osseous dysplasia. Later-stage lesions exhibiting significant mineralization.

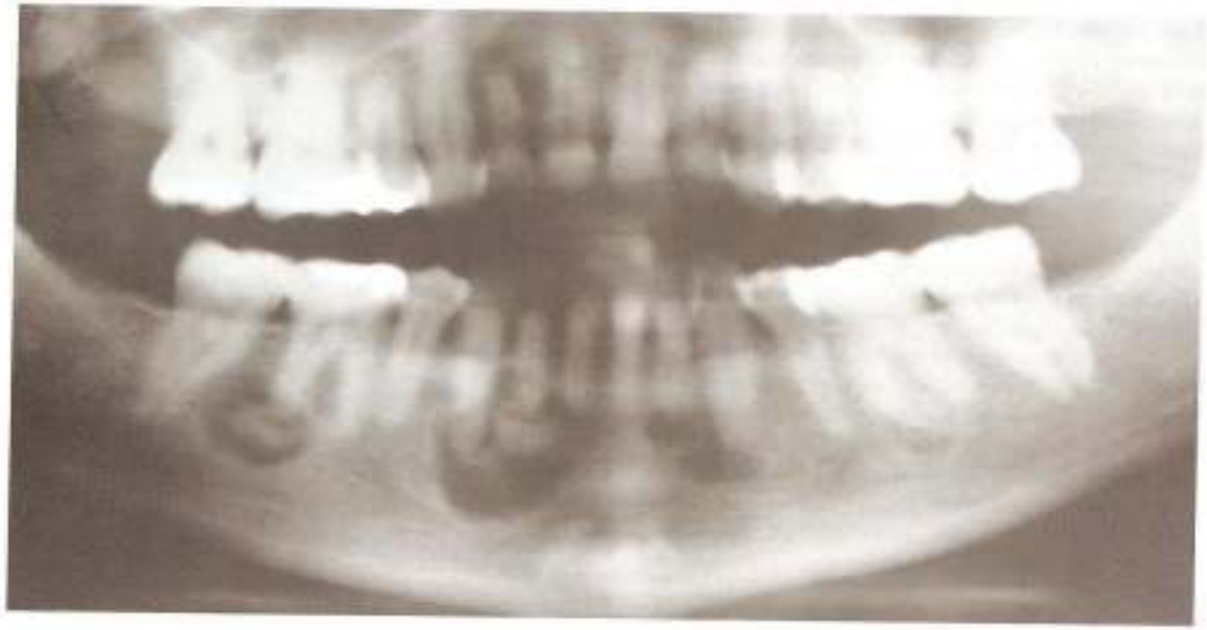

Fig. 14-45 Florid cemento-osseous dysplasia. Multiple mixed radiolucent and radiopaque lesions involving the anterior and posterior regions of the mandible.

Fig. 14-46 Florid cemento-osseous dysplasia. Yellowish, avascular cementum-like material is beginning to exfoliate through the oral mucosa.

Cementa-osseous dysplasia. High-power photomicrograph showing spicules of bone and cementum-like hard tissue within moderately cellular fibrous connective tissue, Note the hemorrhage around the bony trabeculae.

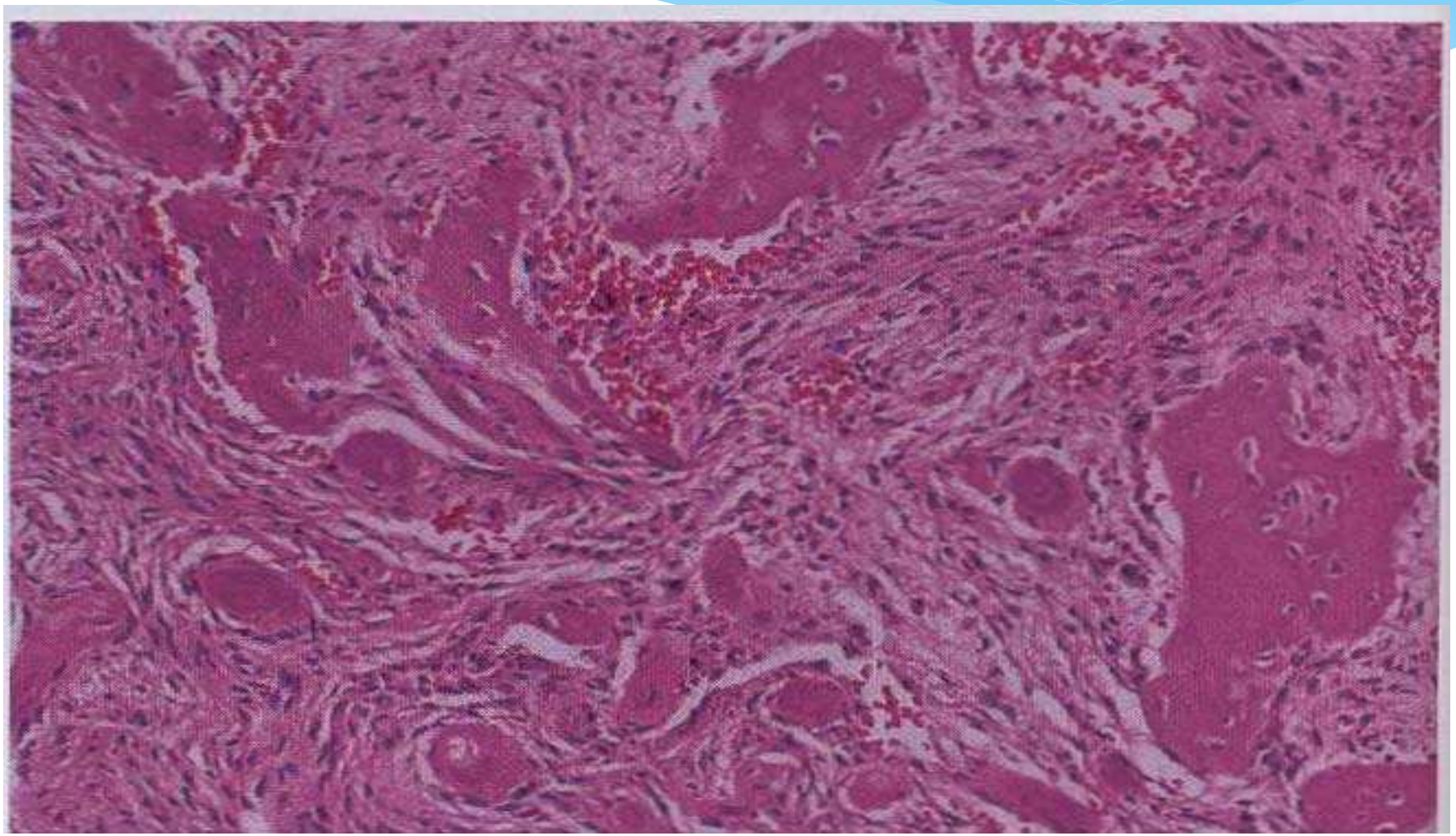

Osteogenesis imperfecta: comprises a heterogeneous group of heritable disorders characterized by impairment of *collagen maturation.*

In addition to bone fragility, some affected individuals also have blue sclera , altered teeth, hypoacusis (hearing loss), long bone and spine deformities, and joint hyperextensibility

- The radiographic hallmarks of osteogenesis imperfecta include osteopenia, angulation or deformity of the long bones, multiple fractures, and wormian bones in the skull .

Osteogenesis imperfecta.

A. Opalescent dentin in a patient with osteogenesis imperfecta.

B. Bite-wing radiograph of the same patient showing shell teeth with thin dentin and enamel of normal thickness.

Blue sclera in a patient with osteogenesis imperfecta

- Osteopetrosis is a marked increase in bone density resulting from a defect in remodeling caused by failure of normal osteoclast function

- Facial deformity develops In many of the children, manifesting as a broad face, hypertelorism, snub nose, and frontal bossing. Tooth eruption almost always is delayed. Failure of resorption and remodeling of the skull bones produces narrowlngs of the skull foramina that press on the various cranial nerves and result in optic nerve atrophy and blindness, deafness, and facial paralysis.

Osteopetrosis. This 24 -year-old white man has the infantile form of osteopetrosis. He has suffered from mandibular osteomyelitis And multiple draining fistulae are present on his face.

Osteopetrosis: Low-power showing sclerotic bone that is replacing the normal cancellous bone. The inset shows a nodular pattern of the dense bone obliterating the marrow spaces.

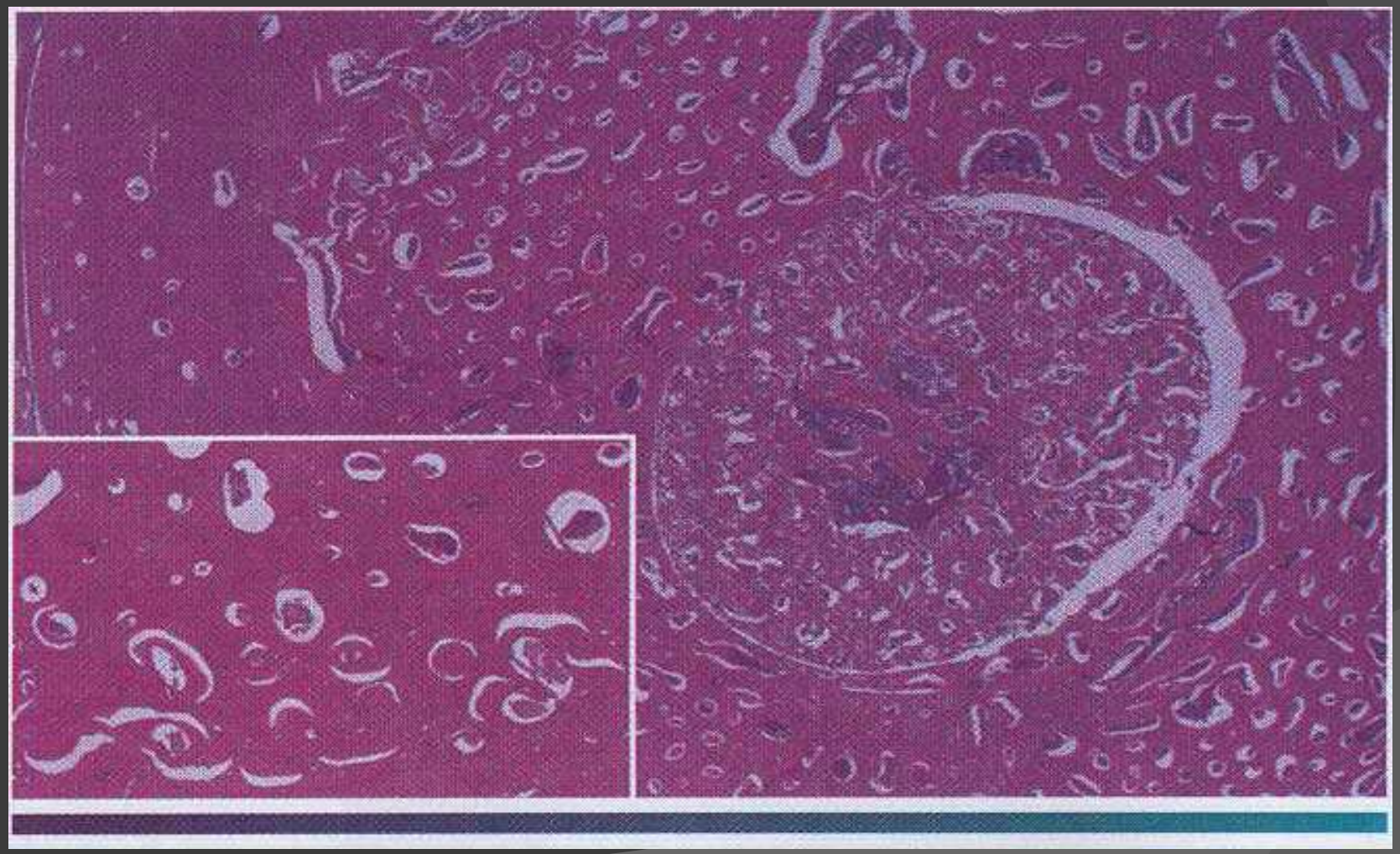

Cleidocranial Dysplasia

- The bone defects in patients with cleidocranial dysplasia chiefly involve the clavicles and skull, although a wide variety of anomalies may be found in other bones. The clavicles are absent, either unilaterally or bilaterally, in about 10% of all cases

Cleidocranial dysplasia: The patient can almost approximate her shoulders in front of her chest.

A narrow, high-arched palate, and there is an increased prevalence of cleft palate.

Prolonged retention of deciduous teeth and delay or complete failure of eruption of permanent teeth are characteristic features.

Upon review of dental radiographs, the most dramatic finding is the presence of numerous unerupted permanent and supernumerary teeth, many of which frequently exhibit distorted crown and root shapes

Cleidocranial dysplasia :Panoramic radiograph showing multiple unerupted teeth

Paget's disease of bone (osteitis deformans

- is a disease characterized by abnormal and resorption and deposition of bone, resulting in distortion and weakening of the affected bones

- Symptoms vary, and some patients may remain relatively asymptomatic. Bone pain, which may be quite severe, is a common complaint. Affected bones become thickened, enlarged, and weakened. Involvement of weight-bearing bones often leads to a bowing deformity

FIGURE 4-15
Paget disease. Maxillary enlargement with associated separation of teeth. (Courtesy Dr. Gordon Rick.)

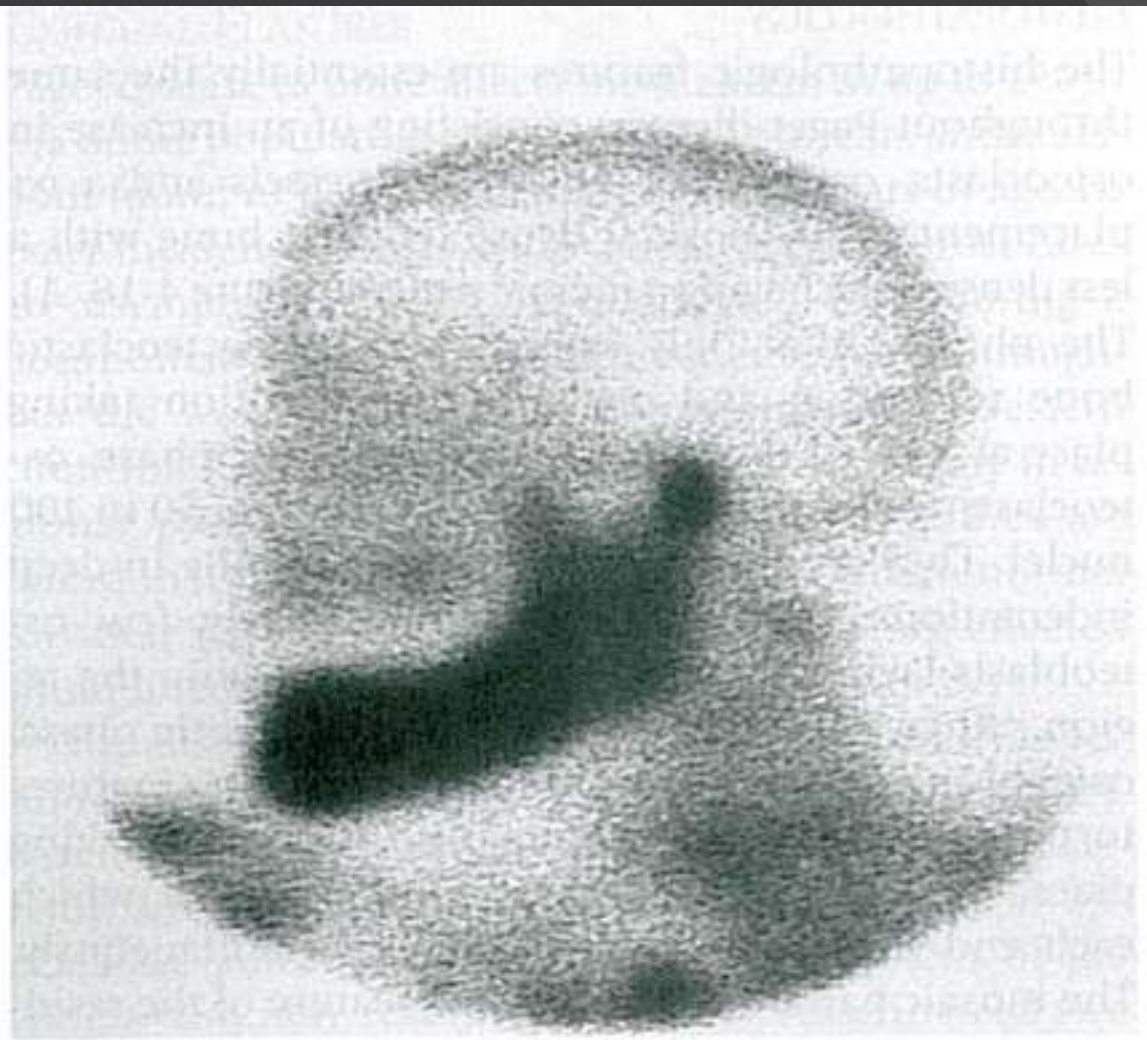

FIGURE 4-17

Paget disease. Scintigraphy demonstrates notable increases in uptake of isotope ("hot spots") in mandible, vertebrae, and clavicle of patient with active disease.

Paget's disease. Lateral skull film shows marked enlargement of the cranium with new bone formation above the outer table of the skull and a patchy, dense, "cotton wool“ appearance.

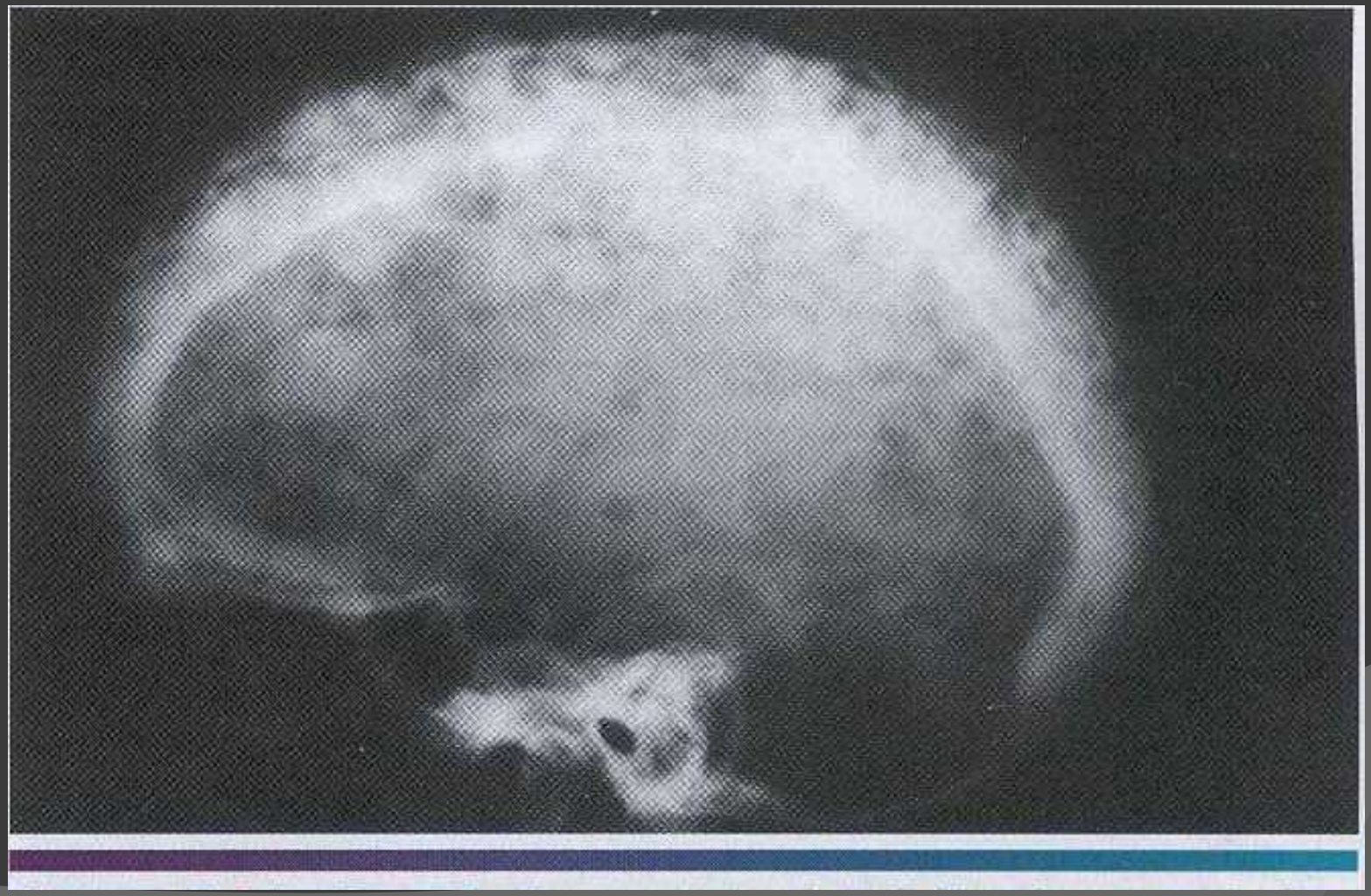

Paget's disease. Periapical film showing the "cotton wool" appearance of the bone.

- Microscopic examination shows an apparent uncontrolled alternating resorption and formation of bone. In the active resorptive stages. numerous osteoclasts surround bone trabeculae and show evidence of resorptive activity. Simultaneously, osteoblastic activity is seen with formation of osteoid rims around bone trabeculae.

- A highly vascular fibrous connective tissue replaces the marrow. A characteristic microscopic feature is the presence of basophilic **reversal lines** in the bone.
- These lines indicate the junction between alternating resorptive and formative phases of the bone and result in a "jigsaw puzzle. " or "mosaic." appearance of the bone

A

B

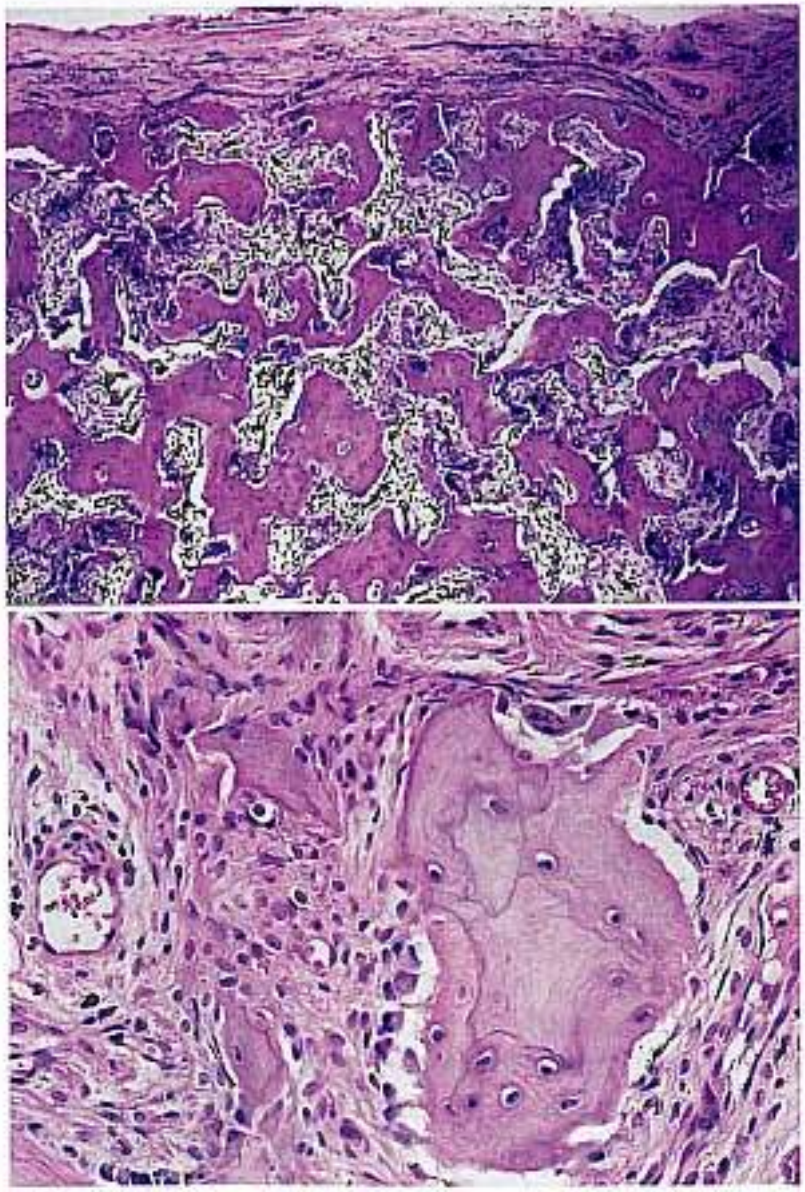

FIGURE 4-18

Paget disease. A, Replacement of normal cortical lamellar bone by a thickened layer of irregular bone fragments surrounded by fibrous tissue with increased numbers of osteoblastic and osteoclastic cells. **B,** High-power photomicrograph of fragment of pagetoid bone exhibiting reversal lines caused by multiple alterations of osteoblastic and osteoclastic activity, resulting in a characteristic mosaic pattern.

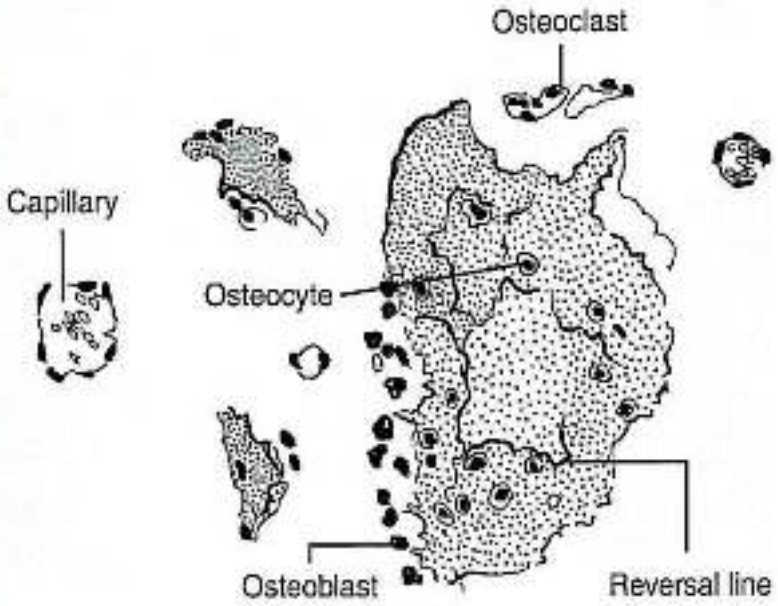

Paget's disease. Prominent osteoblastic and osteoclastic activity surround the bone trabeculae. Note the resting and reversal lines.

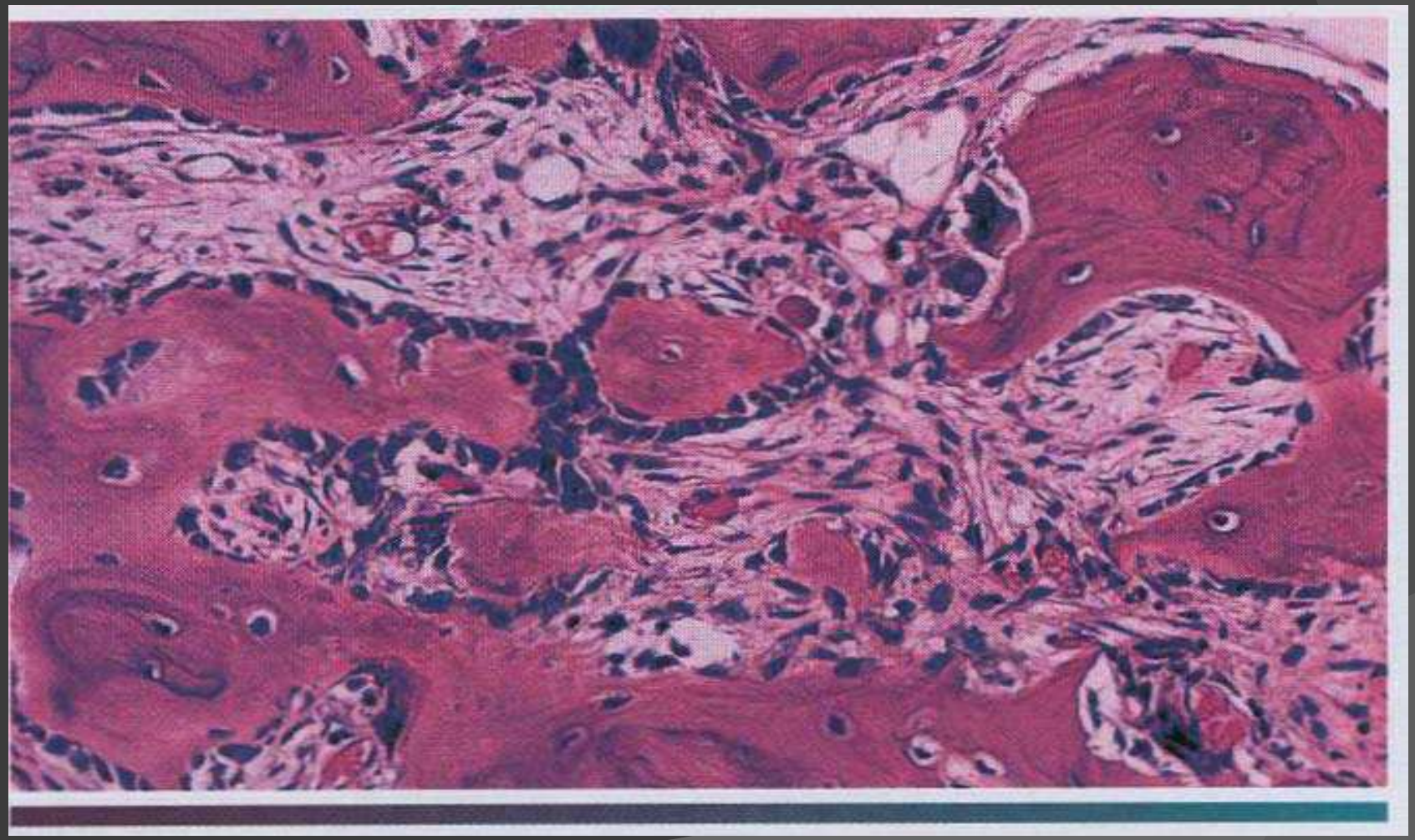

Thank you